

## **Non-invasive mechanical ventilation reduces respiratory motion and increases heart-stomach separation for stereotactic arrhythmia radiotherapy; a healthy volunteer study**

T. Weststrate<sup>1</sup>, B.V. Balgobind<sup>1</sup>, W.F. Hoeksema<sup>2</sup>, P.G. Postema<sup>2</sup>, M.J. Parkes<sup>1</sup>, M.F. Stevens<sup>3</sup>, E.M.T. Dieleman<sup>1</sup>, J.J.C. Verhoeff<sup>1</sup>, A. Bel<sup>1</sup>, I.W.E.M. van Dijk<sup>1</sup>

- 1 Department of Radiation Oncology, Cancer Center Amsterdam, Amsterdam UMC – location University of Amsterdam, Amsterdam, The Netherlands
- 2 Department of Clinical and experimental cardiology, Amsterdam UMC – location University of Amsterdam, Amsterdam, The Netherlands
- 3 Department of Anaesthesiology, Amsterdam UMC – location University of Amsterdam, Amsterdam, The Netherlands

First author e-mail: [t.weststrate@amsterdamumc.nl](mailto:t.weststrate@amsterdamumc.nl)

### **Introduction**

Stereotactic arrhythmia radiotherapy (STAR) is an emerging non-invasive treatment for patients with therapy-refractory ventricular tachycardia (VT). A major challenge in STAR is respiratory motion, which degrades targeting accuracy and often requires increased margins or dose compromises to protect adjacent organs at risk (OAR), particularly the stomach for inferior wall targets. Motion-management strategies that both reduce respiratory motion and increase the separation between target and OAR are therefore highly desirable.

### **Aim**

To quantify the effect of non-invasive mechanical ventilation at 60 breaths per minute with 15 cmH<sub>2</sub>O positive end-expiratory pressure (PEEP; NIMV<sub>60P</sub>) on respiratory motion of the left diaphragm and the minimal heart–stomach separation.

### **Materials and Methods**

Retrospective MRI data from 22 healthy volunteers were analysed. Each volunteer underwent imaging during free-breathing, inhalation breath-hold, exhalation breath-hold, and NIMV<sub>60P</sub>. Respiratory motion of the left diaphragm was quantified from six minute free-breathing and NIMV<sub>60P</sub> coronal cine MRI using deformable image registration. Minimal heart–stomach separation was measured on 3D MRI acquired during NIMV<sub>60P</sub> and both breath-hold conditions. Surrogate internal volumes derived from inhalation and exhalation breath-holds were used to approximate heart–stomach proximity during free-breathing. Statistical comparisons between respiratory strategies were performed using Wilcoxon signed-rank tests with significance at  $p < 0.05$ .

### **Results**

NIMV<sub>60P</sub> reduced the median cranio-caudal diaphragm motion by 50% compared to free-breathing (30 mm vs 15 mm;  $p < 0.001$  (Figure 1)). The median minimal heart-stomach separation during NIMV<sub>60P</sub> was 16.8 mm, significantly greater than during inhalation breath-hold (10.3 mm,  $p = 0.04$ ) and exhalation breath-hold (4.6 mm;  $p < 0.01$  (Figure 2)). During free-breathing, the surrogate internal volumes of heart and stomach overlapped (27/41 MRI sessions) or were minimally separated (14/41 MRI sessions).

### **Conclusion**

Non-invasive mechanical ventilation with PEEP substantially reduces respiratory motion and increases heart-stomach separation. These findings support NIMV<sub>60P</sub> as a promising motion-management strategy for STAR, with potential to improve geometric targeting accuracy and reduce stomach dose, particularly for inferior wall VT targets.

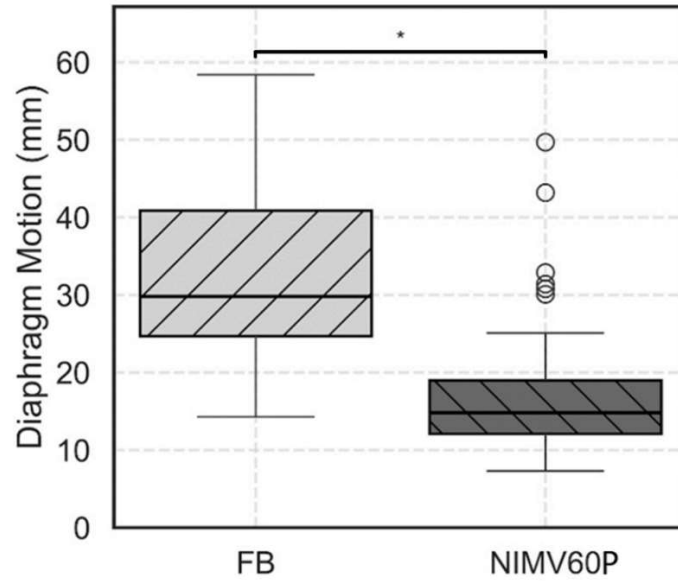


Figure 1: Boxplot showing the left diaphragm motion during free-breathing (FB) and NIMV<sub>60P</sub> for the measured on 41 2D cine MRI scans of N=22 volunteers. Boxes extend from quartile 1 to 3, the horizontal line represent median value and whiskers extend to 90% of the distribution, outliers beyond the 90<sup>th</sup> percentile are shown as dots.  
 \* Denotes statistically significant differences ( $p < 0.05$ ).

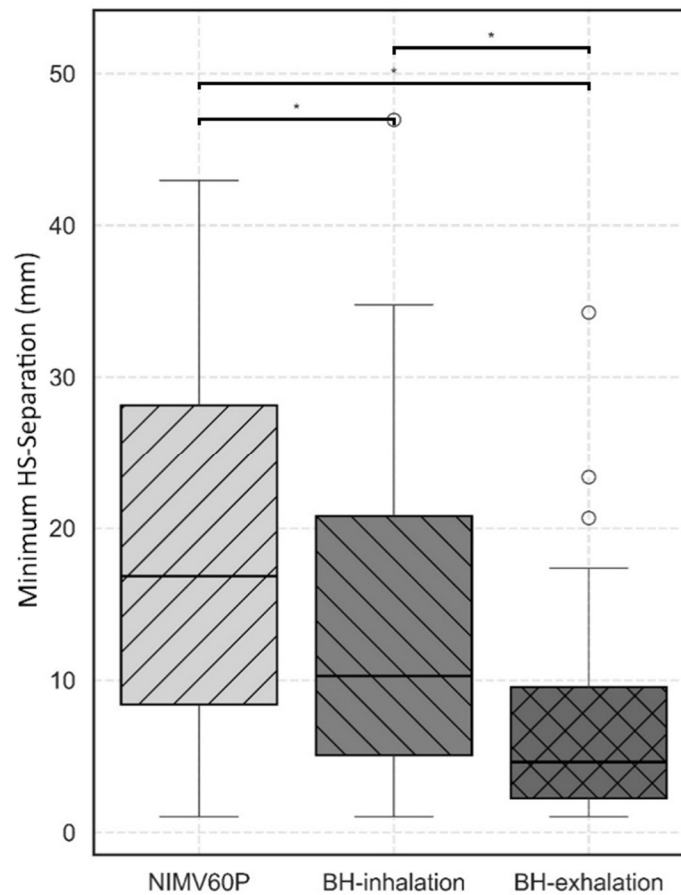


Figure 2: Boxplots showing the minimal heart-stomach separation as measured during NIMV<sub>60P</sub>, BH-inhalation and BH-exhalation measured on 41 3D MRI scans of N=22 healthy volunteers. Boxes extend from quartile 1 to 3, the horizontal line represents median value and whiskers extend to 90% of the distribution.  
 \* Denotes statistically significant differences ( $p < 0.05$ ).